



The value of transbronchial needle aspiration cytology in the diagnosis of stage I and II sarcoidosis

Vrednost transbronhijalne aspiracione citologije u dijagnozi sarkoidoze stadijuma I i II

Željka Tatomirović*†, Vesna Škuletić*†, Dragana Peković†, Vukoica Karličić‡, Branka Djurović†§, Saša Ristić*, Ljiljana Tomić*, Jelena Džambas*, Snežana Cerović*†

Military Medical Academy, *Institute for Pathology and Forensic Medicine, ‡Clinic for Pulmonary Disease, §Institute for Occupational Medicine, Belgrade, Serbia; University of Defence, †Faculty of Medicine of the Military Medical Academy, Belgrade, Serbia

Abstract

Background/Aim. Sarcoidosis is a multisystem inflammatory disease of unknown etiology, with the lungs and intrathoracic lymph nodes the most commonly involved. The aim of this study was to assess the contribution of conventional transbronchial needle aspiration (TBNA) cytology in the diagnosis of sarcoidosis presenting as mediastinal/hilar lymphadenopathy. **Methods.** In this retrospective study, 58 patients with suspicion of stage I and II sarcoidosis underwent first flexible, and then, a rigid bronchoscopy, during which TBNA of mediastinal or hilar lymph node with a 19 gauge (G) needle was done. Material from the needle was put on glass slide and prepared for the cytological and histopathological examination. **Results.** Out of 58 patients submitted to TBNA of mediastinal or hilar lymph nodes, adequate material for cytological diagnostics was obtained in 53 (91.37%). Out of 53 adequate cytological samples, in 38 (71.69%) noncaseous granulomatous inflammation (NGI) was found, while in corresponding histopathological samples, NGI was found in 48 (90.56%), which was significantly higher ($p < 0.05$). Of cytological smears, out of the

cell types typical for granulomatous inflammation, in 26 (63.15%) patients the clusters of the epithelioid cells were found, in 8 (21.05%) there were both, clusters of epithelioid cells and giant multinuclear histiocytes, and in 6 (15.76%) only single scattered epithelioid cells or small clusters of several epithelioid cells were found. The sensitivity of TBNA cytology in our group of patients with sarcoidosis was 76%, specificity 100% and accuracy 77.34%. **Conclusion.** TBNA is an efficient and safe procedure in the diagnosis of sarcoidosis, minimally invasive and with a little risk of complications. Using 19 G needle enables obtaining material for histological and cytological analyses, as well which contribute to the sensitivity of diagnosing sarcoidosis. The value of this type of diagnostics depends on qualification and experience both of bronchoscopist and cytologist/pathologist, as well, of the interpreter of such a material.

Key words: sarcoidosis; diagnosis; differential; lymph nodes; mediastinum; biopsy, fine-needle; sensitivity and specificity.

Apstrakt

Uvod/Cilj. Sarkoidoza je multisustemsko oboljenje nepoznate etiologije koje najčešće zahvata pluća i intratorakalne limfne čvorove. Cilj ovog rada bio je da se proceni doprinos konvencionalne transbronhijalne aspiracione (TBNA) citologije u dijagnozi sarkoidoze prikazane kao medijastinalna/hilarna adenopatija. **Metode.** U ovoj retrospektivnoj studiji, na 58 bolesnika sa sumnjom na stadijum I i II sarkoidoze urađena je prvo fleksibilna bronhoskopija, a potom, u toku rigidne bronhoskopije, TBNA medijastinalnih ili hilarnih limfnih čvorova iglom od 19 gejdža (G). Materijal iz igle je istisnut na predmetno staklo i pripremljen za citološku i pa-

tohistolosku dijagnostiku. **Rezultati.** Od 58 bolesnika kojima je urađena TBNA medijastinalnih ili hilarnih limfnih čvorova, kod 53 (91,37%) dobijen je adekvatan material za citološku dijagnostiku. Od 53 adekvatna citološka uzorka, kod 38 (71,69%) nađena je nekazeozna granulomatozna inflamacija (NGI), dok je u odgovarajućim patohistološkim uzorcima NGI nađena kod 48 (90,56%), što je bio statistički značajno veći broj ($p < 0,05$). U citološkim uzorcima, od ćelija tipičnih za granulomatoznu inflamaciju, u uzorcima 26 (63,15%) bolesnika nađene su nakupine epiteloidnih ćelija, kod 8 (21,05%) uz nakupine epiteloidnih ćelija nađeni su i džinovski multinuklearni histioci, a kod 6 (15,76%) samo pojedinačne epiteloidne ćelije ili male grupe od po nekoliko epiteloidnih

ćelija. Senzitivnost TBNA citologije u našoj grupi bolesnika sa sarkoidozom bila je 76%, specifičnost 100% i tačnost 77,34%. **Zaključak.** Metoda TBNA je efikasna i sigurna za dijagnozu sarkoidoze, minimalno invazivna i s malim rizikom od komplikacija. Upotrebom igle od 19 G dobija se materijal i za citološku i za histološku analizu. Vrednost ovog tipa dijagnostike zavisi od obučenosti i iskustva kako pulmologa koji

uzima materijal, tako i od citologa i patologa koji taj materijal interpretiraju.

Ključne reči:

sarkoidoza; dijagnoza; dijagnoza, diferencijalna; limfni čvorovi; medijastinum; biopsija tankom iglom; senzitivnost i specifičnost.

Introduction

Sarcoidosis is multisystemic inflammatory disease of unknown etiology and pathomechanism. It is characterized by noncaseating granulomas which may be found in virtually all organs. The granulomatous inflammation in sarcoidosis may result from a prolonged immunogenic response to a persistent, yet unknown antigen, which leads to immune system exhaustion¹. There is no gold standard diagnostic test for sarcoidosis, although a recent investigation has shown that identification of serum amyloid A may be a specific marker for sarcoidosis-related granulomatous inflammation².

The lungs and intrathoracic lymph nodes are the most commonly involved organs in sarcoidosis. When clinical and radiological picture is suspicious of sarcoidosis, a histologic diagnosis of noncaseating granulomatous inflammation (NGI) is required to exclude lymphomas and lung cancer, but also the other diseases with similar histology like mycobacteria and fungal infections or chronic beryllium disease^{3,4}.

Previously applied surgical procedures for obtaining tissue samples such as thoracotomy, thoracoscopy and mediastinoscopy are now being replaced by less invasive ones bronchoscopic techniques such as endobronchial (EBB), or transbronchial lung biopsy (TBLB), or minimally invasive ones like conventional transbronchial needle aspiration (TBNA), or endobronchial ultrasound-guided TBNA (EBUS-TBNA), and endoscopic ultrasound-guided fine needle aspiration (EUS-FNA).

TBNA is mostly used for the diagnosis and staging of bronchogenic carcinoma, using rigid or flexible bronchoscopy, with histology, 18, 19 gauge (G) or cytology (21, 22, 26 G) needles. Thin, cytology needles are more easy for use, and excellent for samplings, but advantage of histology needle is obtaining the material for both cytology and histology which increases the possibility of diagnosing, especially in benign lung disease such as sarcoidosis. In a recently published systematic review and meta-analysis of efficacy and safety of conventional TBNA in sarcoidosis, a good diagnostic yield (62%) with practically no complications in more than 900 patients was found⁵.

The aim of this study was to assess the contribution of conventional TBNA cytology by a 19 G needle in the diagnosis of sarcoidosis presenting as mediastinal/ hilar lymphadenopathy.

Methods

Design of study

In this retrospective study, 58 patients with suspicion of stage I and II sarcoidosis according to clinical and radiological findings, in the period between January 2013 and June

2015, were included. To establish the definitive diagnosis of sarcoidosis, at the Department of Interventional Pulmology at the Clinic for Pulmonary Disease, Military Medical Academy, Belgrade, Serbia, the patients underwent TBNA of hilar or mediastinal lymph nodes to obtain material for cytological and pathohistological diagnostics. Before the bronchoscopic procedures, along with laboratory and functional evaluation, patients were submitted to multislice thoracic scan for precise localization and dimension of hilar and mediastinal lymph nodes which were found in all the examined patients, with the diameter of 15–45 mm. Cytological and pathohistological analyses were done in the Institute for Pathology and Forensic Medicine, Military Medical Academy, Belgrade, Serbia.

The procedure of sampling

In short analgesedation, video bronchoscopy (Olympus BF260) with bronchoalveolar lavage (with infusion of 150 mL saline in the middle lobe) was first done. After that, rigid bronchoscopy (Karl Storz, GmbH&Co.KG, Tuttingen, Germany) and TBNA of mediastinal or hilar lymph nodes using a 19 G needle was performed, with taking samples for cytological and pathohistological evaluation.

In 49 patients and 9 patients TBNA of subcarinal (number 7) and hilar lymph nodes (number 10), respectively, were done. There were no immediate or late complications. Material from the needle was expelled on glass slide. The compact particle of material was thoroughly removed from slide by scalpel and put into bottle with formaline for histological diagnostics. The rest of material was directly smeared on slides for cytological analysis. Bronchoscopy and sampling for both diagnostics were done by the pulmonologist with the assistance of a medical technician. There were no cytotechnologist or cytologist at that time, so evaluation of the cytological material was not performed at the same time (“rapid *on site* cytopathologic examination – ROSE”).

Material processing for cytological and pathohistological analysis

Samples for cytological analysis were air-dried and stained with May-Grünwald-Giemsa, and for histopathological analysis samples were placed in 4% formalin, being classically processed in continuity by the standard protocol for fixation, paraffin tissue embedded samples, slicing, and stained with hematoxyllin-eosin (HE) and Ziehl-Nilseen.

During TBNA every patient had one sample of material for histology, and all smears made from the rest of the mate-

rial were considered as one sample for cytology, so in that way we had the equal number of patients and samples. Samples were considered inadequate for cytological evaluation if there were only bronchial epithelial cells and macrophages without lymphocytes, or rare lymphocytes (if it were less than 30% of all cells on smears)⁶.

Cytological diagnosis of NGI which corresponds to sarcoidosis was established only if there were epithelioid cells amongst lymph node cells, solely or in clusters, with or without giant, multinuclear hystiocytes, without the presence of caseous necrosis.

Statistical evaluation

Beside the usual parameters of descriptive statistics for the age of patients (mean value \pm SD), the standard definitions of TBNA cytology sensitivity (TP/TP + FN), specificity (TN/TN + FP) and accuracy (TP+TN/TP+TN + FP + FN) were used (TP – true positive; TN – true negative; FP – false positive; FN – false negative). The unit of analysis was a patient. The true positive were considered all cytological findings with the picture of NGI corresponding to sarcoidosis, being confirmed with histopathological finding. False negative were considered all adequate cytological samples without elements of granulomatous inflammation and histopathologically verified NGI as Ziehl -Nilseen negative, corresponding to sarcoidosis. True negative were considered adequate cytological samples without elements for granulomatous inflammation, confirmed by histology. There were no false positive cytological findings.

For the evaluation of statistical significance of certain parameters (at the level of $p < 0.05$), χ^2 test, t -test and Wilcoxon's test were used. Analyses were performed with the computer program IBM SPSS 20 and Microsoft Office Excel 200.

Results

During the period of two and a half years, in 58 patients with suspicion of I and II stage of sarcoidosis, based on clinical and radiological findings, the diagnosis was confirmed histopathologically and/or cytologically on the material taken by bronchoscopic procedures. The mean age of patients (\pm SD) was 40.83 ± 11.43 (23–65) years. There were 36 (62%) men, mean age 37.42 ± 8.84 years and 22 (38%) women, mean age 46.41 ± 13.09 years. There were more men than women, while women were older, but these differences in the numbers ($p = 0.066$; $p > 0.05$) and age ($p = 0.281$; $p > 0.05$) were not statistically significant.

Out of 58 patients submitted to TBNA of mediastinal or hilar lymph nodes, adequate material for cytological diagnostics was taken from 53 (91.37%) and inadequate from 5 (8.62%) of the patients, therefore the comparison of cytological *versus* histological findings was done for 53 patients, from whom only two (3.45%) of the samples for histological diagnostics were inadequate.

Out of 53 adequate cytological samples, in 38 (71.69%) NGI was found, while out of 53 corresponding histopathological samples, NGI was found in 48 (90.56%). This difference in the number of positive histological *versus* cytological findings reached a statistical significance ($p = 0.002$; $p < 0.05$) (Table 1).

Out of 5 negative histological samples, 2 of them were inadequate (there were no cells from lymph node or there were so little of them). In cytological smears, out of the cell types typical for granulomatous inflammation, the clusters of the epithelioid cells were found in 26 (63.15%) of the patients which was the most frequent finding (Figure 1). In the smears of 8 (21.05%) of the patients there were both, clusters of the epithelioid cells and giant multinuclear hystiocytes (Figure 2), and in 6 (15.76%) only scattered or small clusters of several epithelioid cells were found (Figure 3). Beside elements of granulomatous

Table 1

The results of cytological and histopathological analysis of samples obtained by transbronchial needle aspiration (TBNA) of mediastinal or hilar lymph nodes

Parameter	Cytology, n (%)	Histopathology, n (%)
Granulomatous inflammation	38 (71.69)	48 (90.56)*
Without elements for granulomatous inflammation	15 (28.31)	5 (9.44)
Total number	53 (100)	53 (100)

*Significantly higher number of histological findings with granulomatous inflammation *versus* cytological findings ($p < 0.05$)

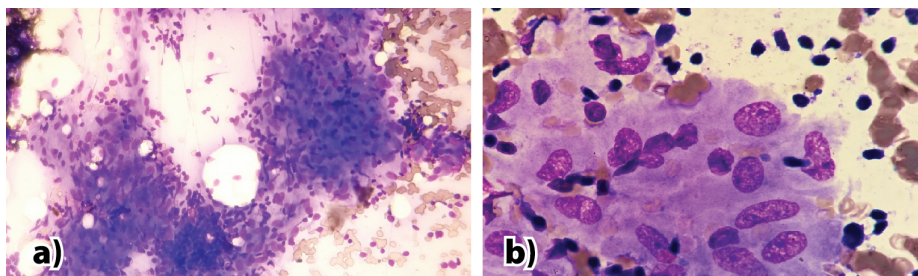


Fig. 1 – Transbronchial needle aspiration (TBNA) smear obtained from mediastinal/hilar lymph nodes: a) Large clusters of epithelioid cells and scattered small lymphocytes (May-Grünwald-Giemsa, $\times 200$); b) A group of epithelioid cells, some of them with typical elongated nucleus (May-Grünwald-Giemsa, $\times 1,000$).

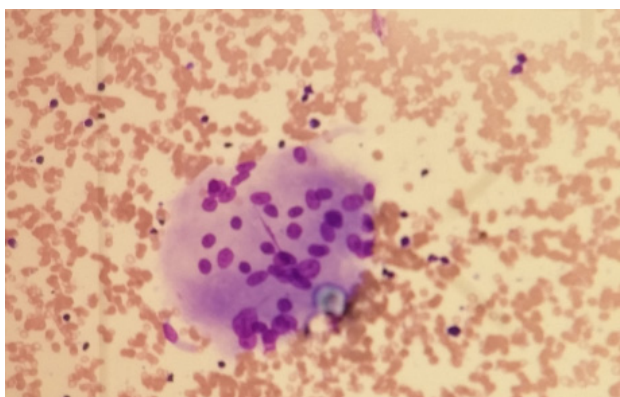


Fig. 2 – Transbranchial needle aspiration (TBNA) smear obtained from mediastinal/hilar lymph nodes. Multinucleated giant cell and scattered lymphocytes (May-Grünwald-Giemsa, $\times 100$).

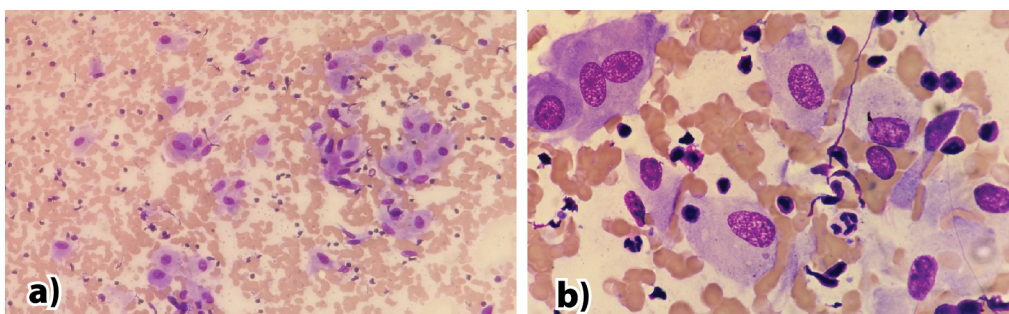


Fig. 3 – Transbranchial needle aspiration (TBNA) smear obtained from mediastinal/hilar lymph nodes: a) Scattered small groups and single epithelioid cells, lymphocytes and rare cylindrical cells (May-Grünwald-Giemsa, $\times 100$); b) Single epithelioid cells, lymphocytes and one cylindrical cell (May-Grünwald-Giemsa, $\times 1,000$).

inflammation, small matured lymphocytes or polymorphous picture of lymph node with lymphohistiocytic aggregates were the most frequently present.

In 15 (28.30%) adequate cytological samples there were no elements of granulomatous inflammation. Out of that, 12 findings were false negative, 3 were true negative. There were no false positive cytological findings. The sensitivity of TBNA cytology in our group of patients with sarcoidosis presenting as mediastinal/hilar lymphadenopathy was 76%, specificity 100%, and accuracy 77.34%.

Discussion

Sarcoidosis is a multisystemic disease which might represent a serious diagnostic problem. Though it can affect any of the organs, the most predilected are lungs, and it usually requires rulling out other diseases which could give the similar clinical and radiological simptomatology. The necessity for less invasive, yet sufficiently effective technics for obtaining diagnostic material have put the emphasis on TBNA, whether it is done “on blind” during conventional flexible bronchoscopy, or ultrasound guided (EBUS-TBNA, EUS-FNA).

Recent investigations have proved a significantly higher sensitivity and accuracy of ultrasound-guided TBNA whether from esophagus or great airways *versus* conventional one, in the diagnosis of pulmonary sarcoidosis which is manifested with hilar/mediastinal lymphadenopathy. In that way, Annema et al. ⁷ suggest EUS-FNA as the next diagnostic

procedure after nondiagnostic bronchoscopy and Gnass et al. ⁸, on the basis of the results obtained by comparison of conventional and US needle biopsy technics, suggest EUS-FNA as the method of choice for patients with suspicion of sarcoidosis. Ribeiro et al. ⁹ suggest EBUS-TBNA as the first diagnostic line, while Navani et al. ¹⁰ suggest EBUS-TBNA in combination with the standard, initial bronchoscopic technics (EBB and TBB) as the first line of examination for patients with suspicion of sarcoidosis and intrathoracic lymphadenopathy. However, technology of US-guided TBNA is still expensive in order to be used as the first diagnostic line, especially for poor countries.

On the basis of the results of meta-analysis of efficacy and security of conventional TBNA, Agarwal et al. ⁵ suggest that in order to diagnose sarcoidosis, TBNA must be included in combination with TBLB as the routine method there, where it is not possible to introduce EBUS-TBNA.

Though TBNA was introduced over 60 years ago, first during rigid ¹¹, later during flexible bronchoscopy ¹², lots of authors consider it still as underused technics of obtaining material especially for the diagnosis of benign diseases such as sarcoidosis ^{5, 13-15}.

It has been shown that the value of TBNA in the diagnosis of sarcoidosis could be influenced by various factors such as the stage of disease, needle type (whether it is cytological or histological), the number of patients, trained staff and experience both of bronchoscopist and cytologist/pathologist ^{5, 16-19}.

In the last 10 years TBNA has been performed routinely in the Bronchoscopic Department of our hospital for staging of lung cancer, the diagnosis of hilar and mediastinal lymphadenopathy, as well as in the diagnosis of sarcoidosis.

In this retrospective study we presented our experience with this type of diagnostics for patients suspicion of sarcoidosis I and II stage, based on clinical and radiological data, with emphasis on estimation of value of cytological diagnostics.

Various age groups could be affected by sarcoidosis, but mostly persons younger than 40 years old. The average age of our patients was 40. However, though women got sick of sarcoidosis more frequently than men, in our group there were more men than women, while women were of older age, but those differences were of no statistical significance. The fact of not being in agreement with the literature regarding sex distribution was most probably due to relatively small number of analyzed patients.

Important fact in the morphological confirmation of sarcoidosis is the adequacy of material obtained with this procedure (TBNA). In our tested group, the adequate cytological material was obtained in 91.37% of the patients which is very close to the percentage (94%) of adequate cytological samples of lymph nodes in the results of the study by Trisolini et al.¹⁶, in the group of the equal number of patients (53) with sarcoidosis, submitted to TBNA by 19 G needle.

Such good results for TBNA in both of papers were most probably associated with the highly skilled bronchoscopist, as well as the fact that samples were obtained mostly from subcarinal (number 7) and (in our group, less frequently) paratracheal nodes (number 10), and it is well-known that both localizations give best results with conventional TBNA^{16, 20, 21}. However, it should be underlined here that these authors had adequate samples for histopathological analysis only in 51% of the patients, while we obtained it from 95.5% of the patients, for this type of analysis.

Considering that for both investigations samples were obtained from the same localised nodes, with the same needle type (19 G), it is the experience of pulmonologist that affected the quality of the obtained material for this procedure.

Trisolini et al.¹⁶ explain the smaller contribution of histological TBNA samples to the diagnosis of sarcoidosis by frequent use of thin cytological needles in the recent years, which could lessen the manipulative skill using the histological needles that were used previously for such investigations.

In our study the contribution of cytological TBNA material to the diagnosis of sarcoidosis is significantly smaller than histopathological one (71.69% positive cytological findings *versus* 90.56% positive histological findings).

If we include two of the patients diagnosed with NGI only cytologically to the number of the patients diagnosed with NGI histopathologically, then we confirmed sarcoidosis in 94.5% of the patients (in 50 out of 53 patients), by the method of TBNA.

Such a good result obtained by TBNA in our tested group, beside the manipulative skill and great experience of the bronchoscopist, is surely the consequence of the very design of this retrospective study to choose only patients with a

high clinical suspicion of sarcoidosis, confirmed cytologically and/or histologically, since the purpose of this study was to estimate cytology in the diagnosis of sarcoidosis using histological needle.

On the contrary to our results, Trisolini et al.¹⁶ had much higher contribution of cytological TBNA material than histological one in their group: in 79% (42 out of 53) of the patients sarcoidosis was confirmed cytologically, and in only 30% (16 out of 53) histopathologically.

Total diagnostic value of histopathological and cytological diagnosis of sarcoidosis in that study was 79% (42 out of 53 patients).

In our group of patients, we had more inadequate cytological samples as well as significantly less cytological samples with the elements of NGI, due to the fact that the best quality material, the compact part of material obtained with TBNA was separated for histopathology, and the rest, usually with the tinge of blood, was left and used for cytology.

Cetinkaya et al.²² made the diagnosis of sarcoidosis in 87.5% of the patients (7 out of 8 patients) based on material obtained from TBNA during flexible bronchoscopy, also with the 19 G needle, but they did not declare the exact part of it regarding cytological and histopathological diagnostics. Having chosen a 22 G needle, they made the diagnosis of sarcoidosis in 76% of the patients (16 out of 20 patients)²³.

In our group of patients, out of 5 histopathological samples with no granulomatous inflammation found, two were inadequate (but the cytological findings for these patients were positive), while the three of samples were adequate but without signs of NGI, and for these patients cytology was negative as well, so they were true negative cytological findings (in all of these three patients the diagnosis of sarcoidosis was proven, later).

We had no false positive cytological findings, and the cause for false negative findings was not the interpretative fault but the insufficiency of elements for the granulomatous inflammation.

The sensitivity of cytological diagnostics in our group of patients was 76%, and accuracy 77.34%. In the paper by Smojver-Jezek et al.²⁴ the sensitivity of TBNA cytology in the diagnostics of sarcoidosis manifested with mediastinal/hilar lymphadenopathy was 78.7%, the accuracy 86.2%, and in 63.6% of the patients the only morphological diagnosis of sarcoidosis was a cytological one. However, TBNA was performed by the 26 G needle, which is used for obtaining samples only for cytological diagnostics.

Agarwal et al.⁵ within the scope of systematic check-ups and meta-analyses estimated the diagnostic value and security of TBNA for sarcoidosis. On the basis of analysis of 12 studies that used 19 G needle and 9 studies that used cytological needles, they concluded that it was better to use 19 G needle for TBNA diagnostics of sarcoidosis. This type of needle gives the possibility to obtain histological and cytological material as well, therefore to contribute to sensitivity of TBNA.

In our cytological material, granulomatous inflammation was presented most frequently with dense aggregates of epitheloid cells (epitheloid histiocytes), less frequently with

multinuclear, giant histiocytes. Least frequent, in 15.76% of positive samples, we found epithelioid cells, single or in very small clusters out of few, while Smojver-Jezek et al.²⁴ found such a cytological picture in 25% of positive findings, considering it to be a specific finding consistent with sarcoidosis. Though such finding alone is not sufficient for the diagnosis of granuloma, we assumed that these authors interpreted findings along with the clinical and radiological data, as well. By all means, adding such samples into positive ones, contributes to the overall sensitivity and accuracy of cytological diagnostics for both studies.

To interpret cytological findings it is essential for the personnel to be qualified and experienced. Insufficient experience in the identification of granuloma in cytological specimens out of interthoracic lymphadenopathy could negatively influence the value of TBNA diagnostics, whether it is conventional one or EBUS-TBNA. Therefore Tremblay et al.¹⁸ in their study compared conventional *versus* EBUS-TBNA on the patients with the suspicion of sarcoidosis, and showed that identification of granuloma in the same cytological material was significantly different between two of the pathologists involved in the study, and Chee et al.¹⁹, in cytological estimation of EBUS-TBNA in sarcoidosis, found good interobserver agreement between cytopathologists, but even better results after the revision of slides by the pulmonary cytopathologist.

Cancellieri et al.²⁵ analyzed sarcoid granulomas in cytological specimens from interthoracic lymph nodes, and stated that two of the major mistakes in the diagnosis of granuloma on TBNA within cytological specimens are: a simple aggregate of epithelioid histiocytes – exhibiting a photo of a lymphohistiocytic aggregate (which is the common picture within the reactive hyperplasia of lymph node), and cohesive clusters of cylindrical epithelial cells.

We consider less likely for such mistakes to happen in the interpretation if it is done by the qualified and experienced pathologist/cytologist.

Histopathological verification of granulomatous lymphadenitis, as well as the biopsy of granulomatous changes within the lungs, could present itself as a huge differential and diagnostic issue, especially in the absence of significant clinical data.

The finding of granulomatous inflammation within interthoracic lymph nodes, require the exclusion from berylliosis, sarcoidosis-like lymphadenitis and also reaction on

malignancy and anthracotic pigment^{26,27}. In our analyzed group of patients with sarcoidosis, histopathological confirmation of granulomatous disease was missing for 5 (8.62%) patients. For two patients it was due to inadequate material, and for three other, the material was adequate but without signs of NGI. The reasons for negative finding could be various.

In the early stage of the disease microscopic changes within lymph node could exhibit all of the characteristics of nonspecified lymphadenitis.

Epithelioid nodule could be discrete and localized cortically. Multinuclear cells need not to be within each of the granulomas, not even in the whole histopathologically processed specimen of a lymph node. Sometimes, in the late phase of sarcoid lymphadenitis, the multiplication of the collagen fibers with hyalinization could be seen instead of granuloma^{26,27}. To differentiate the type of necrosis it usually requires obligatory use of histochemical staining method like Ziehl-Neelsen which we used for our patients to differentiate the nature of suspicious zones within granulomas looking like caseous necrosis, in order to exclude the presence of acidfast bacilli.

Conclusion

TBNA is an efficient and secure procedure in the diagnosis of sarcoidosis, minimally invasive and with a little risk of complications.

With this procedure, using a thin 19 G needle, the material for histological and cytological analyses is obtained.

Though we found out cytological diagnostics of sarcoidosis significantly less sensitive than histological one, its advantage is in the fact that it is fast, as well as that it could substitute histological one, in cases with no adequate material for histological analysis, along with the positive clinical and radiological findings for stage I and II sarcoidosis.

It was found that significantly less sensitivity of cytological diagnosis in our research was the consequence of the fact that the compact, the best quality material was separated for histological, and only the rest of material was submitted for cytological analysis.

The value of this type of diagnostics depends much on qualification and experience of the bronchoscopist and cytologist/pathologist, as well as on interpretation of such a material.

R E F E R E N C E S

1. *Marc AJ*. Advances in the diagnosis and treatment of sarcoidosis. *F1000Prime Rep*2014, 6: 89.
2. *Chen ES, Song Z, Willett MH, Heine S, Yung RC, Liu MC, et al*. Serum amyloid A regulates granulomatous inflammation in sarcoidosis through Toll-like receptor-2. *Am J Respir Crit Care Med* 2010; 181(4): 360–73.
3. *Costabel U, Hunningbake GW*. ATS/ERS/WASOG statement on sarcoidosis. Sarcoidosis Statement Committee. American Thoracic Society. European Respiratory Society. World Association for Sarcoidosis and Other Granulomatous Disorders. *Eur Respir J* 1999; 14(4): 735–7.
4. *Mukhopadhyay S, Gal AA*. Granulomatous lung disease: An approach to the differential diagnosis. *Arch Pathol Lab Med* 2010; 134(5): 667–90.
5. *Agarwal R, Aggarwal AN, Gupta D*. Efficacy and safety of conventional transbronchial needle aspiration in sarcoidosis: A systematic review and meta-analysis. *Respir Care* 2013; 58(4): 683–93.
6. *Baker JJ, Solanki PH, Schenk DA, Van Pelt C, Ramzy I*. Transbronchial fine needle aspiration of the mediastinum. Importance of lymphocytes as an indicator of specimen adequacy. *Acta Cytol* 1990; 34(4): 517–23.

7. *Annema JT, Veselić M, Rabe KF.* Endoscopic ultrasound-guided fine-needle aspiration for the diagnosis of sarcoidosis. *Eur Respir J* 2005; 25(3): 405–9.
8. *Gnass M, Szłubowski A, Soja J, Kocoń P, Rudnicka L, Ćmiel A, Kuźet al.* Comparison of conventional and ultrasound-guided needle biopsy techniques in the diagnosis of sarcoidosis: A randomized trial. *Pol Arch Med Wewn* 2015; 125(5): 321–8.
9. *Ribeiro C, Oliveira A, Neves S, Campainha S, Nogueira C, Torres S, et al.* Diagnosis of sarcoidosis in the endobronchial ultrasound-guided transbronchial needle aspiration. *Rev Port Pneumol* 2014; 20(5): 237–41.
10. *Navani N, Booth HL, Kocjan G, Falzon M, Capitanio A, Brown JM, et al.* Combination of endobronchial ultrasound-guided transbronchial needle aspiration with standard bronchoscopic techniques for the diagnosis of stage I and stage II pulmonary sarcoidosis. *Respirology* 2011; 16(3): 467–72.
11. *Schieppati E.* Mediastinal puncture thru the tracheal carina. *Rev Asoc Med Argent* 1949; 63(663–664): 497–8. (Spanish)
12. *Wang KP, Terry P, Marsh B.* Bronchoscopic needle aspiration biopsy of paratracheal tumors. *Am Rev Respir Dis* 1978; 118(1): 17–21.
13. *Smyth CM, Stead RJ.* Survey of flexible fiberoptic bronchoscopy in the United Kingdom. *Eur Respir J* 2002; 19(3): 458–63.
14. *Dasgupta A, Mehta AC.* Transbronchial needle aspiration. An underused diagnostic technique. *Clin Chest Med* 1999; 20(1): 39–51.
15. *Hsu L, Liu C, Ko J.* Education and experience improve the performance of transbronchial needle aspiration: A learning curve at a cancer center. *Chest* 2004; 125(2): 532–40.
16. *Trisolini R, Tinelli C, Cancellieri A, Paioli D, Alifano M, Boaron M, et al.* Transbronchial needle aspiration in sarcoidosis: Yield and predictors of a positive aspirate. *J Thoracic Cardiovasc Surg* 2008; 135(4): 837–42.
17. *Morales CF, Patefield AJ, Strollo PJ, Schenk DA.* Flexible transbronchial needle aspiration in the diagnosis of sarcoidosis. *Chest* 1994; 106(3): 709–11.
18. *Tremblay A, Stather DR, MacEachern P, Khalil M, Field SK.* A randomized controlled trial of standard vs endobronchial ultrasound-guided transbronchial needle aspiration in patients with suspected sarcoidosis. *Chest* 2009; 136(2): 340–6.
19. *Chee A, Khalil M, Stather DR, MacEachern P, Field SK, Tremblay A.* Cytologic assessment of endobronchial ultrasound-guided transbronchial needle aspirates in sarcoidosis. *J Bronchology Interv Pulmonol* 2012; 19(1): 24–8.
20. *Patelli M, Lazžari Agli L, Poletti V, Trisolini R, Cancellieri A, Lacava N, et al.* Role of fiberoptic transbronchial needle aspiration in the staging of N2 disease due to non-small cell lung cancer. *Ann Thorac Surg* 2002; 73(2): 407–11.
21. *Trisolini R, Lazžari Agli L, Cancellieri A, Poletti V, Tinelli C, Baruzzi G, et al.* The value of flexible transbronchial needle aspiration in the diagnosis of stage I sarcoidosis. *Chest* 2003; 124(6): 2126–30.
22. *Cetinkaya E, Yildiz P, Kadakal F, Tekin A, Soysal F, Elibol S, et al.* Transbronchial needle aspiration in the diagnosis of intrathoracic lymphadenopathy. *Respiration* 2002; 69(4): 335–8.
23. *Cetinkaya E, Yildiz P, Altin S, Yilmaz V.* Diagnostic value of transbronchial needle aspiration by Wang 22-gauge cytology needle in intrathoracic lymphadenopathy. *Chest* 2004; 125(2): 527–31.
24. *Smojver-Ježek S, Peros-Golubčić T, Tekavec-Trkanjec J, Mazuranić I, Alilović M.* Transbronchial fine needle aspiration cytology in the diagnosis of mediastinal/hilar sarcoidosis. *Cytopathology* 2007; 18(1): 3–7.
25. *Cancellieri A, Leslie KO, Tinelli C, Patelli M, Trisolini R.* Sarcoidal granulomas in cytological specimens from intrathoracic adenopathy: Morphologic characteristics and radiographic correlations. *Respiration* 2013; 85(3): 244–51.
26. *Asano S.* Granulomatous lymphadenitis. *J Clin Exp Hematopathol* 2012; 52(1): 1–16.
27. *Newman LS, Rose CS, Maier LA.* Sarcoidosis. *N Engl J Med* 1997; 336: 1224–34.

Received on November 5, 2015.

Accepted on February 29, 2016.

Online First April, 2016.